CHAPTER 41

The foot and ankle

Learning objectives

To understand:

- The basic anatomy and biomechanics of the foot and ankle
- The common problems affecting the foot and ankle in each age group
- The principles behind the treatment of each condition, be it conservative or surgical
- The significance of progressive neurological diseases

ANATOMY

There are 26 (25 with variant) main bones in the foot (seven tarsal bones, five metatarsals and 14 phalanges [13 in the biphalangeal fifth toe variant]) plus the two sesamoids of the hallux and a variable number of other sesamoid and accessory bones.

Movements at the ankle joint are mainly dorsiflexion and plantarflexion, but are more complex than this. The joint is actually a truncated section of a cone, meaning that the motion is not simply a hinge; in addition, movement of the ankle leads to rotation of the fibula at the syndesmosis. This means that the foot externally rotates with dorsiflexion and internally rotates with plantarflexion.

Stability is conferred upon the ankle by the congruence of the mortice and the integrity of principally the medial, lateral and inferior tibiofibular ligaments.

The subtalar joint is divided into anterior, middle and posterior facets and, along with the talonavicular and calcaneocuboid joints, makes up the triple joint complex. These joints are responsible for inversion and eversion of the hind- and midfoot. The joints are co-dependent such that limitation of one affects movement at the others. Fusion of the triple complex slightly affects movement at the ankle and vice versa.

The second tarsometatarsal (TMT) joint is recessed relative to the first and third and acts as a 'keystone'. Disruption of this joint (Lisfranc's injury) leads to loss of the transverse arch and an acquired flat foot.

The lower leg is divided into four compartments:

- the superficial posterior – gastrocnemius, soleus and plantaris;
- the deep posterior – tibialis posterior, flexor digitorum longus and flexor hallucis longus (FHL);
- the lateral – peroneus brevis and peroneus longus;
- the anterior – tibialis anterior, extensor hallucis longus, extensor digitorum longus and peroneus tertius.

There is only one muscle on the dorsum of the foot, the extensor digitorum brevis. The muscles on the plantar aspect of the foot are divided into four layers, the first being the most superficial, and the course of the neurovascular structures is a favourite examination topic. The plantar fascia is a very important structure that takes its origin from the heel and inserts into the bases of the proximal phalanges of the toes. At toe-off, the fascia tightens and accentuates the medial plantar arch and helps provide a rigid lever arm, the so-called 'windlass mechanism'. This is essential in the preservation of the integrity of the arch of the foot and function of the toes.

The blood supply of the foot is from the anterior tibial, the posterior tibial and the peroneal arteries. The following nerves supply sensation to the foot: posterior tibial, saphenous, sural, superficial and deep peroneal (*Figure 41.1*).

Summary box 41.1

Anatomy of the foot

- There are 26 major bones in the foot
- There are four layers of muscles in the sole of the foot
- The blood supply of the foot is from the anterior and posterior tibial arteries plus the peroneal artery

Jacques Lisfranc, 1790–1847, Professor of Surgery and Operative Medicine, Paris, France.

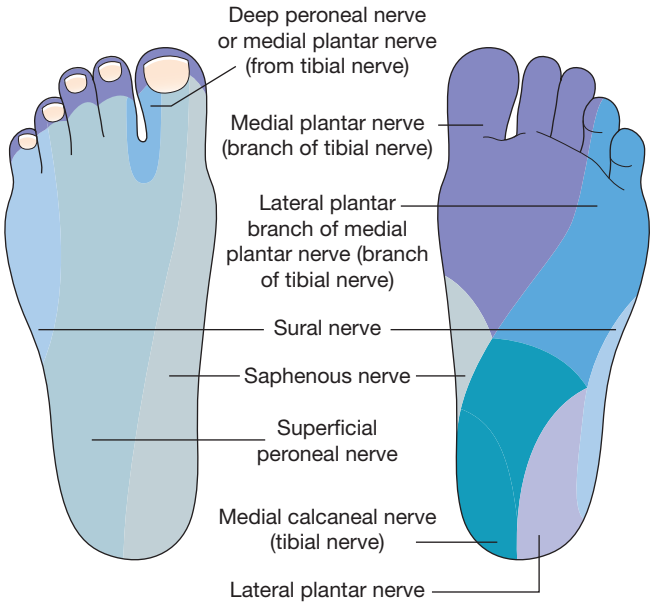

Figure 41.1 Cutaneous nerve supply of the foot (courtesy of Bartleby.com).

BIOMECHANICS

The walking cycle is divided into the stance (60%) and swing (40%) phases. The stance phase is divided into three intervals: (i) heel strike to foot flat; (ii) foot flat until the body passes over the ankle; and (iii) ankle joint plantarflexion to toe-off. During walking up to 12% of the gait cycle is spent with both feet in the stance phase, but with running there is a period when neither foot is in contact with the ground – the 'float' phase. During running the cycle time is shortened but the forces generated are very much increased.

Summary box 41.2

Biomechanics

- The gait cycle is divided into swing and stance phases
- Running generates increased forces, shortens the gait cycle and has a float phase when neither foot touches the ground

Examination

The examination of the foot is described in *Chapter 35*. The patient should be watched walking, and both the foot and the footwear of the patient need examining when looking for abnormal load and wear.

PAEDIATRIC CONDITIONS

These are discussed in *Chapter 44*.

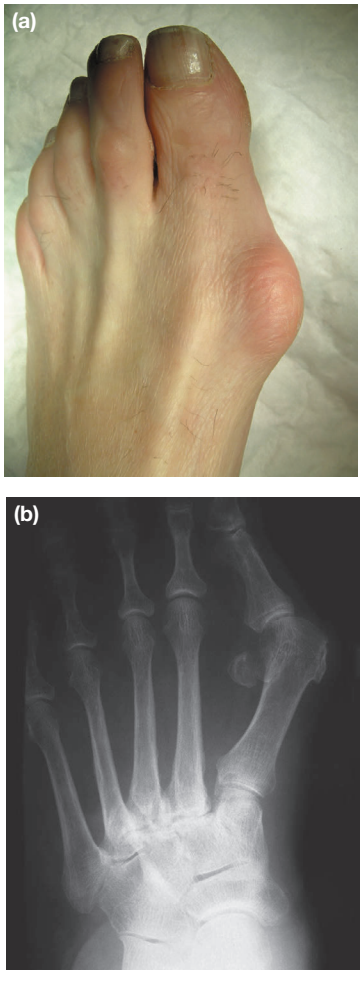

Figure 41.2 (a, b) Hallux valgus and bunion.

PATHOLOGY IN THE ADULT

The forefoot

Hallux valgus

Hallux valgus is deviation of the big toe away from the midline, i.e. towards the lesser toes, and is usually associated with a bunion, a swelling made up of both bone and bursa on the medial aspect of the first metatarsal head (*Figure 41.2*). It is a common condition that affects women more than men, and that is often bilateral. It is believed that the tendency to hallux valgus is inherited and that fully enclosed shoes accelerate the development of the condition, although not all agree.

With increasing deformity the first ray becomes defunctioned and elevated, and overload of the second metatarsophalangeal (MTP) joint often results in pain, swelling and eventually plantar plate disruption and dislocation. This can present with a prominent callosity beneath the second MTP joint and eventually hammering of the second toe.

Non-operative treatment of hallux valgus includes a wider toe box and pressure relief. Surgical intervention is commonly offered, but has a 10% rate of dissatisfaction.

For mild deformities a distal osteotomy (e.g. chevron) is usually adequate. For moderate deformities the surgeon is

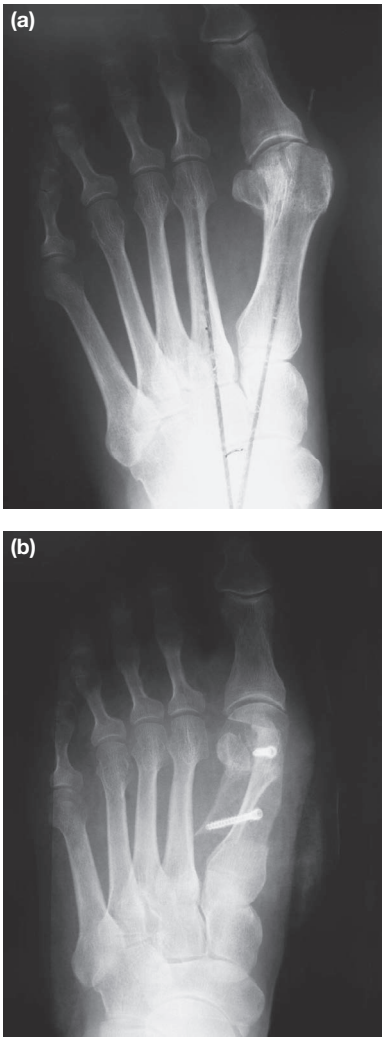

Figure 41.3 Pre- (a) and postoperative (b) radiographs of a scarf osteotomy.

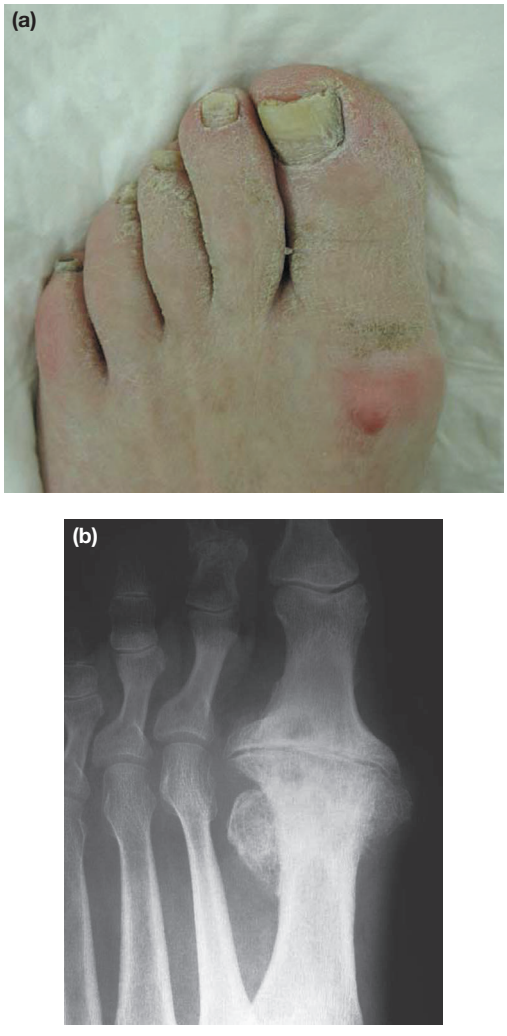

Figure 41.4 Clinical (a) and radiographic (b) appearance of hallux rigidus.

more likely to use a shaft, e.g. scarf (*Figure 41.3*) or Ludloff, or a basal (proximal chevron or crescentic) osteotomy. Severe deformities can be corrected by shaft and basal osteotomies but sometimes a fusion of the first TMT joint (modified Lapidus) or a first MTP joint fusion can be effective and is the preferred option for hypermobile or unstable TMT1 joint deformities. Minimally invasive techniques are developing and are widespread, especially in Europe, but there are few peer-reviewed series of outcomes from the UK and it has not become mainstream.

Basal osteotomies and fusions have a higher risk of abnormal elevation or depression of the rays, resulting in overload of the rest of the forefoot. However, they do allow a massive correction. They are best stabilised using plates.

Operations such as a Keller's excision arthroplasty, where the proximal third of the proximal phalanx is excised, serve to defunction the toe and sesamoids and are reserved for low-demand, high-risk patients in whom there is a high risk that healing of an osteotomy might fail.

The complications of bunion surgery are infection, cutaneous nerve damage, recurrence or overcorrection of deformity, stiffness and overload of the second MTP joint (transfer lesion); 10% of patients have significant reservations and 20% mild reservations about their outcome. Occasionally patients develop early arthritis following surgery and require revision to fusion.

Hallux rigidus

Hallux rigidus is a painful condition of the hallux MTP joint characterised by loss of motion, especially in dorsiflexion, and osteophyte formation on the dorsum and sides of the joint (*Figure 41.4*).

A **scarf** osteotomy is named after a carpentry term; it is an elongated Z-shaped osteotomy along the metatarsal.
Karl Ludloff, 1864–1945, German orthopaedic surgeon.
Paul W Lapidus, 1893–1981, Russian-born orthopaedic surgeon, Chief of the first Orthopedic Foot Clinic and Service, Hospital for Joint Diseases, New York, NY, USA.
William Lordan Keller, 1874–1959, Head of the Department of Surgery, Walter Reed Hospital, Washington, DC, USA, described this operation in 1904.

Summary box 41.3

Hallux valgus

- Bunions affect women more often than men
- Patients with hallux valgus have inherited a tendency to develop the condition
- Not all patients need surgery
- The choice of operation is determined by the severity of the deformity and presence or absence of any arthritis, instability of the joints or hypermobility

In adults there is often a history of trauma or repetitive microtrauma (sport) but, occasionally, there is a strong family history of the condition. Gout and rheumatological conditions may present in this way. Patients complain of stiffness and pain on weight-bearing.

The most effective non-operative treatment is provision of a stiff-soled shoe with a deep toe box or a rocker-soled shoe, which are now available on the high street.

The mainstays of surgical management are injection/manipulation, cheilectomy (a radical debridement and excision of the part of the joint blocking movement), fusion and interposition arthroplasty (Keller-type procedure or silicone interposition). Prosthetic arthroplasty, with hemi-, total, interposition or spacer arthroplasty, is available but many prostheses have been withdrawn because of high failure rates and few series extend beyond 9 years. Newer prosthetic inserts with claimed joint-preserving capabilities similarly fail to show advantages with regards to pain and have a high revision/reoperation rate but are still preferred by some who wish to retain mobility at MTP1 in the short to medium term.

Fusion is for the severely affected and is an effective means of abolishing pain, but affects the biomechanics and some patients are left with intractable pain beneath the sesamoids. A fusion will still usually allow sports participation.

Summary box 41.4

Hallux rigidus

- Hallux rigidus can affect adolescents as well as adults
- Stiff-soled shoes with a deep toe box are the most comfortable type of shoe
- Cheilectomy and fusion are the mainstays of surgical treatment

Sesamoid/sesamoid complex problems

Turf toe

Acute injuries (turf toe) can be managed non-operatively or surgically depending on the grade of the injury and the occupation of the patient. Grade 4 acute rupture may require surgery.

Turf toe is a plantar plate disruption usually from hyperextension injuries at MTP1 and may involve sesamoid fractures. Low-grade injuries can be treated non-operatively but high-grade injuries require reconstruction, especially in athletes (see *Chapter 36*).

Chronic conditions range from stress fracture to avascular necrosis (AVN) and sesamoiditis but are probably all the same phenomenon. Management includes offloading with orthotics, injections of steroids and, rarely, shaving/excision. Excision surgery carries a high risk.

Lesser toe deformities

Hammer, mallet and claw toes are frequent and are usually nonindicative but may be secondary to other deformities in the foot or to underlying neurological disease. Nonoperative treatment involves appropriate padding and footwear modification. For symptomatic flexible deformities soft-tissue surgery such as flexor/extensor tenotomies with/without capsulotomy is usually adequate, but for fixed deformities bony procedures are required such as interposition arthroplasty, fusion or excision arthroplasty.

Isolated lesser toe MTP extension/subluxation may result from a ruptured plantar plate at MTP joints and repair techniques have evolved recently, but the results are moderate at best and the trend is back to non-operative management where possible. Ultrasound and magnetic resonance imaging (MRI) are now well established for these injuries.

Freiberg's disease

Freiberg's disease (*Figure 41.5*) is an ischaemic necrosis of the epiphysis, resulting in pain and swelling of the joint. It will often settle with rest. Reshaping osteotomies are described, or excision of the proximal phalangeal head for severe adult cases with joint destruction. Excision of the whole metatarsal head should never be performed.

Morton's neuroma and metatarsalgia

Metatarsalgia usually occurs secondary to joint problems, overload or irritation of a nerve. Morton's neuroma is a painful

Figure 41.5 Freiberg's disease.

Albert Henry Freiberg, Professor of Orthopaedic Surgery, University of Cincinnati, Cincinnati, OH, USA, gave his account of this condition in 1926.
Thomas George Morton, 1835–1903, surgeon, Pennsylvania Hospital, Philadelphia, PA, USA, described this condition in 1876.

condition that, in most cases, arises from compression of the common digital nerve, most commonly between the third and fourth metatarsal heads and the second/third and is usually secondary to other forefoot pathology.

The diagnosis is confirmed by ultrasound or MRI. Non-operative treatments include advice about footwear, an orthosis (premetatarsal dome) to splay the metatarsal heads or an injection of steroids. Cryotherapy and even alcohol injections have been reported.

Surgery involves resection (the affected toes will be permanently partly hemi-numb if the nerve is removed) but this is not without risk of patient dissatisfaction, pain and recurrence, with around 5% reporting bad outcomes, often permanent. European colleagues often simply transect the intermetatarsal ligament instead.

Summary box 41.5

Morton's neuroma

- Morton's neuroma most commonly affects the second or third web space
- Surgical excision of neuroma is often successful but has a risk of pain syndrome
- Guided injections form the mainstay of treatment for most

Stress fracture

This may occur following sport or may be incipient. It usually presents in the forefoot and may mimic Morton's neuroma or metatarsalgia. An unexplained aetiology might require biochemical or biomechanical evaluation. Forefoot fractures can usually be managed non-operatively.

Stress fractures may occur in any bone. Those of the navicular, talus and tibial sesamoid often present with vague symptomatology but early diagnosis with MRI and management are essential with immediate offloading and protection with early fixation – if required, urgently – if a full fracture is seen developing. Vague, poorly defined midfoot pain in an athlete or military recruit mandates urgent scanning and offloading.

Follow-up investigation of bone metabolism/density and exclusion of myeloma may be required.

The midfoot

The midfoot comprises the cuneiforms and the cuboid and related joints.

Midfoot arthritis

The aetiology is usually not known but the risk factors include microtrauma, rheumatological causes, flat foot, Lisfranc or similar injuries (which may have been missed), Charcot and cavus foot. Patients are best managed non-operatively with orthotics, shoes, analgesia and modifications of their lifestyle.

Pain, often with palpable dorsal osteophytes, is the commonest finding. Injections and orthotics are the mainstay of treatment, with surgery high risk and having moderate outcomes. Fusion or interposition arthroplasty of the lateral two TMT joints has a universally poor outcome.

Charcot

An acute hot, red, swollen foot (which may or may not be painful) may be indicative of Charcot (often secondary to diabetes, which may as yet be undiagnosed) or other neuropathy. Immediate offloading in plaster and urgent management are indicated; National Institute for Health and Care Excellence (NICE) guidelines are available in the UK.

The presence of any unexplained swelling, heat, ulcer or deformity in a diabetic foot mandates an emergency and referral along NICE guidelines; failure to follow such guidelines can lead to significant sums being paid out by indemnity organsiations.

Tendinopathy

Rarely, dorsal pain may be due to tibialis anterior tendinosis at its insertion; management is usually non-operative. Injection carries a slight risk of rupture, which is ameliorated by a surgical boot with deep vein thrombosis (DVT) prophylaxis.

Ganglions

Midfoot ganglions are common and may cause neuralgia over dorsal bosses. Injection/aspiration should be attempted. Surgery may be required but recurrence is high and secondary neuralgia not infrequent.

The hindfoot and ankle

Ankle arthritis

The definitive operative treatment for arthritis of the ankle will usually be in the form of total ankle replacement (TAR) or more commonly arthrodesis (fusion); the latter is often carried out via an open approach but arthroscopic techniques have better outcomes, more rapid recovery and fewer complications and almost all surgical units in the UK now offer such techniques. Such techniques are mandatory in the presence of a poor soft-tissue envelope or in the presence of a clotting diathesis.

A UK national trial is currently under way to evaluate the relative outcomes of TAR versus arthrodesis (the TARVA trial), which are as yet undefined; the trial has been complicated further by the withdrawal/failure of the two leading implants.

The advantage of fusion is that it has a known track record, good outcomes (over 90% of patients do well) and minimal morbidity, especially with modern arthroscopic techniques, but not all do well with fusion. Function following isolated fusion is virtually normal for most patients and this is probably due to increased mobility at other joints. However, this may precipitate arthralgia elsewhere.

TARs were until recently three-component devices (except in the USA) but a two-component device is now the market leader in the UK by far. It is not yet known if this is relevant but allows an easier regulatory pathway in the USA. Outcomes

Jean Martin Charcot, 1825–1893, physician, La Salpêtrière, Paris, France.

seem to be related to accuracy of placement and modern instrumentation may be a key factor; custom implants based on preoperative computed tomography (CT) scans are becoming mainstream. TARs allow preservation of joint mobility but at the expense of larger incisions and possible eventual failure. Revision rates of <1% to 7% per annum are reported, with most showing an approximately 3% failure rate per year. Survivorship analysis does not record patients who are doing badly but who do not have further surgery and a recent paper showed revisions are under-reported. The changes in the regulatory pathways in the UK/European Union relating to the development of new implants may limit the development of TARs in these regions to the same levels of efficacy seen by total hip replacements and total knee replacements.

Hindfoot (excluding ankle) arthritis

The triple complex refers to the subtalar (talocalcaneal), calcaneocuboid and talonavicular joints. These joints are often affected by arthritis. Treatment options are limited and, if simple measures have failed, a fusion should be performed. Smokers and patients with diabetes have a massively increased non-union rate for all foot fusion procedures and should be warned of this when they give consent. Late presentation of coalitions usually requires fusion.

Ankle combined with other hindfoot arthritis

If surgical input is required, one option is to treat one set of joints and then see how the patient fares. For example, offer the patient an ankle fusion or replacement and then assess the outcome. Secondary surgery to the other joints can then be performed if required. The alternative is to treat all joints at once. The non-union rates of the ankle following a subtalar fusion or vice versa are high (up to 75%). For this reason, some clinicians advise TAR, not ankle fusion, following a previous subtalar/triple fusion.

Modern techniques now use third-generation hindfoot fusion nails that fuse both the ankle and subtalar joints. These are inserted with an open or arthroscopic fusion technique.

A pantalar fusion is quite disabling but may be necessary in patients with rheumatoid arthritis or with deformities/stress fractures and in those with a failed arthroplasty with subtalar joint involvement, pantalar arthritis or AVN with collapse of the talus.

Summary box 41.6

Midfoot and hindfoot

- Joint disorders are degenerative or inflammatory
- The mainstay of surgical treatment remains fusion, although ankle replacements are becoming more successful
- Rheumatoid arthritis must be medically controlled as well as possible before surgery
- Knee deformities should be corrected before tackling foot problems

Rheumatological presentations in the foot

The early presentations of rheumatological disease may include synovitis of the lesser MTP joints and widespread small joint disease, often in association with enthesopathy such as plantar fasciitis or Achilles tendinosis. However, the classic deformity is of hallux valgus with or without hallux rigidus deformity and subluxation or even dislocation of the lesser MTP joints in the forefoot and arthritis and deformity in the mid/hindfoot.

The patient may present with a bunion and prominent lesser metatarsal heads, which can often be felt to be dislocated on clinical examination and are painful to palpation. Joint-sparing surgery is preferred, with preservation of the metatarsal heads if possible, often shortening and relocating the MTP joints. Destruction of the joints can be treated with proximal phalangeal partial excisions. Fusion of the first MTP joint is the usual requirement. Late recurrence can be managed with excision arthroplasty.

Excision of the metatarsal heads produces an almost instantaneous and gratifying relief of pain. If a plantar approach is used an ellipse of skin can be excised to move the metatarsal padding back over the end of the metatarsal. While most surgeons avoid scars on the plantar aspect of the foot wherever possible, this is one procedure where the results are good. However, such surgery leaves no room for revision in later years.

The requirement for rheumatoid forefoot correction has fallen dramatically in the last 20 years with the advent of disease-modifying drugs; most trainee surgeons will now have never seen a Fowler's procedure (or similar), which was once a mainstream and common procedure.

Midfoot

Rheumatological disease may also affect the midfoot and here the outcome is usually just pain and stiffness. Options are limited to injections and fusion surgery if non-operative measures have failed.

Hindfoot and ankle

Rheumatological disease also affects the hindfoot and ankle. Many patients require surgical hindfoot fusions and the options for the ankle are discussed in *Ankle arthritis*. Outcomes of TAR are favourable in patients with rheumatoid arthritis, although increased deformities may make the outcomes less predictable.

The rheumatological diseases also affect soft tissues. Patients are more prone to developing enthesopathy, tendinitis and tendinosis, and even tendon rupture. The Achilles tendon should never be injected with steroid for fear of rupture; similarly, the tibialis anterior and tibialis posterior tendons are risky for injection.

Tendon disorders

Tenosynovitis/tendinitis is probably a misnomer as the histological data support neither pathology in many cases. It often occurs as a result of injury or overuse or is secondary to inflammatory disease. Rest, anti-inflammatory medication

Alan W Fowler, 1920–2013, orthopaedic surgeon, Bridgend Hospital, UK.

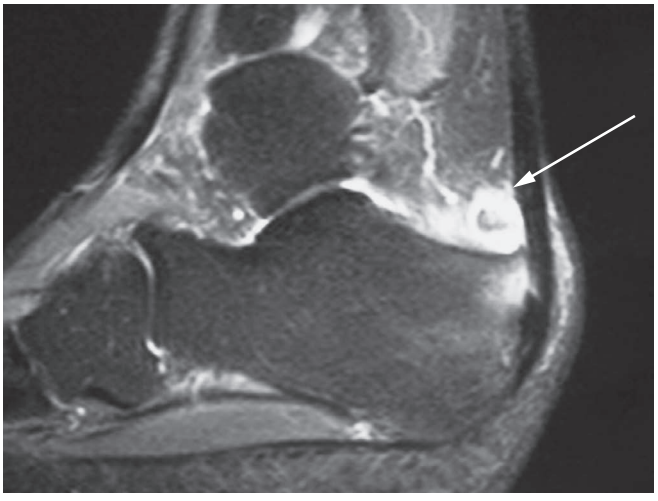

Figure 41.6 Insertional Achilles tendinitis (arrow).

and physiotherapy are often helpful but, in inflammatory conditions, tenosynovectomy may be required.

The tendons most commonly affected by degeneration are the Achilles (*Figure 41.6*), tibialis posterior and the peronei (brevis more than longus).

Ruptured Achilles tendon

The Achilles tendon rupture is relatively frequent in the 40- to 50-year-old age group who are undertaking vigorous sport after a long period away from such activities, but can occur in any age and with little provocation. One-quarter are missed in primary care or in the accident and emergency department and the recording of the Simmonds test is mandatory. The test is non-reliable after 1 week. Management of acute rupture is more frequently non-operative nowadays, provided ultrasound has shown closure of the gap in plantarflexion (although the importance of this even is now debated), and many protocols are described for non-operative management. Surgical fixation is an alternative but large meta-analyses have shown little if any advantage of surgical fixation with an increased complication rate.

Many patients do not suffer the acute rupture classically described in all textbooks and many seem to have a series of micro-tears that gradually lead to total rupture. Studies have shown that older adult patients with Achilles rupture regained 70–90% of the normal power with no treatment whatsoever when reviewed at 1 year; for many patients, this is enough to allow some of them to return to normal function.

Non-operative options for a missed rupture include a sprung ankle–foot orthotic ankle brace, while operative options involve reconstructive surgery with or without FHL tendon augmentation or synthetic ligament replacement.

Achilles tendinosis

Non-insertional tendinosis is frequent, often related to overuse and is usually managed non-operatively. Multiple tendon problems should alert the clinician to the presence of seronegative arthritides. Shockwave therapy is a recent addition to the armoury. Steroid injections may rupture the Achilles tendon and are discouraged; high-volume saline, dry-needling and sclerosant injections have all been described but are used less frequently with the advent of shockwave. Surgery for non-insertional tendinosis has moderate success.

Insertional tendinosis is usually associated with a Haglund's bony deformity or the presence of intratendinous bony spurs/shelves seen on lateral radiograph. Significant intratendinous bony spurs rarely get better without surgical input in the author's experience. Minimally invasive or mini-open excision of the prominent posterolateral corner of the calcaneum in Haglund's deformity, detachment, debridement and reattachment or reshaping osteotomy form the mainstay of modern surgical techniques for insertional problems, but both conditions have a relatively high rate of failure and complication with surgery.

Peroneal tendon problems

The peroneal tendons may develop tendinosis, may subluxate or may become involved in an inflammatory process with or without bony overgrowth at the inferior retinaculum (*Figure 41.7*). An associated varus heel will amplify the problem and will need addressing with an appropriate reconstruction/osteotomy or fusion. Investigation as to whether the varus heel caused the peroneal problem or vice versa should be established or recurrence is guaranteed.

Peroneal tendon subluxation can occur spontaneously or after injury. It may be associated with the groove at the back of the fibula being too shallow to contain the peroneal tendons, but may just be secondary to a superior retinaculum tear. The patient may be able to demonstrate a tendon subluxation over the fibula. Surgical repair is usually required and involves deepening of the groove.

Tendinosis/tendinitis can be managed non-operatively, although injections have occasionally caused rupture. Surgical debridement or repair of splits/tears/ruptures is well described but has only moderate success.

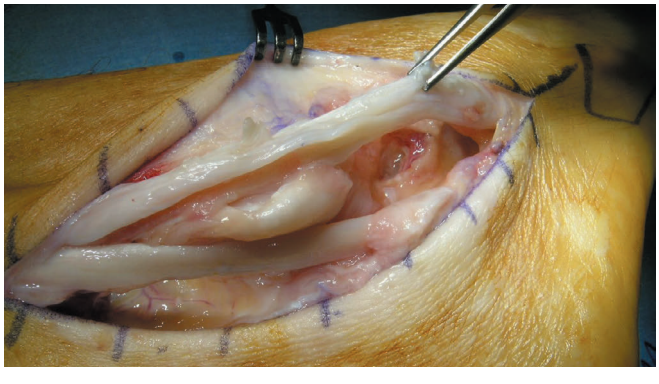

Figure 41.7 Split and degenerate peroneus brevis.

Franklin Adin Simmonds, 1911–1983, orthopaedic surgeon, The Rowley Bristow Hospital, Pyrford, Surrey, UK.
Patrik Haglund, 1870–1937, Swedish orthopaedic surgeon.

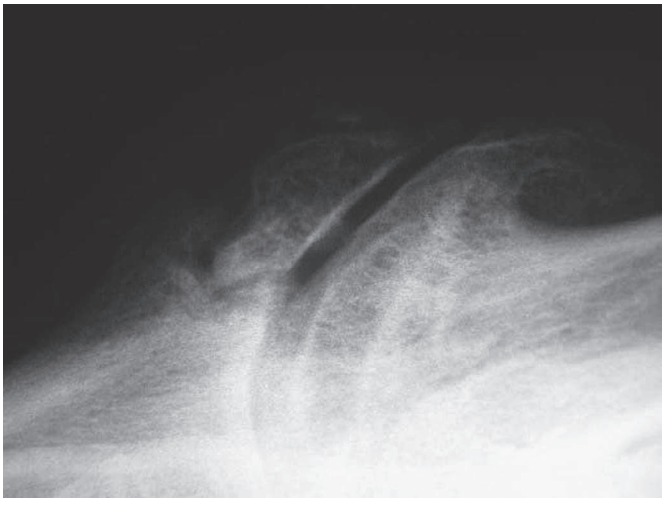

Figure 41.8 Tarsometatarsal arthritis.

Figure 41.9 A tibialis posterior tendon-deficient foot.

Acquired flat foot

There is a wide range of normal appearance of adult feet. Pathological causes of a flat foot include:

- tibialis posterior tendon dysfunction;
- tarsometatarsal arthritis/injury (*Figure 41.8*);
- Charcot neuroarthropathy, e.g. diabetes (see *Diabetes*);
- inflammatory/degenerative arthritis of the subtalar/talonavicular/naviculocuneiform joints;
- spring ligament rupture;
- tarsal coalition.

Summary box 41.7

Acquired flat foot

- Tibialis posterior tendon dysfunction and tarsometatarsal osteoarthritis are common causes of an acquired flat foot
- Orthoses, rest and non-steroidal anti-inflammatory drugs (NSAIDs) can help with symptomatic relief
- Surgery is a major undertaking but is often highly successful at achieving symptomatic relief

The tibialis posterior tendon tends to fail in overweight individuals and those who have flat feet. Often, after unaccustomed exercise, the tendon swells and is painful. The condition occurs mainly in women; the key test, which is that the patient cannot stand on tiptoe on that leg alone, indicates a significant advanced stage tendon problem. Many individuals will require surgical treatment in the form of a medial displacement calcaneal osteotomy, flexor digitorum longus or FHL tendon transfer and spring ligament repair. Failure to treat this condition can lead to spectacular deformity (*Figure 41.9*).

An acute traumatic flat foot may develop in young athletes and military recruits after traumatic injury. Examination shows a new-onset flat foot but with a functioning tibialis posterior tendon with single-leg tiptoe preserved; here the injury is an isolated spring ligament tear and early surgery prevents late-onset secondary deformity.

Ankle instability

Most people who sustain an ankle sprain will recover, particularly if they receive prompt physiotherapy. However, some individuals develop significant instability. On examination an unstable ankle due to ligament disruption will show a marked 'anterior drawer' sign.

If physiotherapy is unsuccessful at resolving the problem, a reconstruction may be needed with ligament augmentation. Anatomical techniques such as the Broström procedure are favoured and may be supplemented with synthetic augments for early mobilisation. Peroneal tendon harvesting for reconstruction is now obsolete with the new reconstruction techniques and implants.

Other aetiologies of instability include osteochondritis dissecans (OCD) lesions, syndesmosis instability and peroneal tendon pathology.

Osteochondral lesion of the talus

Patients with persistent pain (and sometimes instability) in the ankle following an injury should be suspected of having an osteochondral lesion, with MRI or CT usually required for diagnosis.

Repair of cartilage is not yet possible and large meta-analyses of experimental techniques such as grafting, cell culture, implants and stem cells have not yet shown any statistical benefit. Debridement and microabrasion/microfracture form the mainstay of treatment. Large fragments seen early might benefit from early fixation. Juveniles seem to have a high spontaneous recovery rate and surgery should not be necessary.

L Broström, described the surgical treatment of chronic ligament ruptures in 1966.

Synovitis

Many patients have ongoing pain following ankle injury that is simply due to synovitis within the ankle joint, prominence of the syndesmotic ligament into the joint, impaction injury or undiagnosed fracture or OCD lesion. MRI is mandatory for these cases but usually misses the synovitis. Synovitis may be treated non-operatively, with an injection of steroid. Persistent symptoms may require arthroscopic debridement.

Neurological foot conditions

Pes cavus

The development of unilateral pes cavus is likely to be due to an upper motor neurone lesion, so an appropriate neurological examination should be performed and spinal imaging is mandated.

Pes cavus is usually bilateral and most cases will be associated with an underlying neurological condition, the most common being Charcot–Marie–Tooth disease. These patients may present with characteristic progressive small muscle wasting, thin calf musculature, hand symptoms, aches and pains, and cavovarus feet. Examination may show early loss of vibration sense. Precise diagnosis is confirmed with nerve conduction studies and genetic testing.

The key deforming force is always relative preservation of the tibialis posterior tendon. Surgical correction of the deformity is often required. The principal goal of treatment is to obtain a foot that can be placed flat on the ground, and with the power of the muscles around the ankle in balance. It will always be necessary to transfer the tibialis posterior tendon. The most commonly performed procedure is to transfer the tibialis posterior tendon to the dorsolateral side of the foot, with a lateralising heel osteotomy and dorsiflexion osteotomy of the first ray with or without a Jones procedure to the great toe and Hibbs procedure to the lesser toes. Older textbooks all universally relay the mistaken belief that it is peroneal overactivity that is the deforming force … it isn't!

Summary box 41.8

Pes cavus

- Pes cavus needs neurological investigation
- About 80% of cases of pes cavus are associated with a neurological disease
- The commonest cause is Charcot–Marie–Tooth disease
- Unilateral pes cavus – think diastematomyelia/tumour

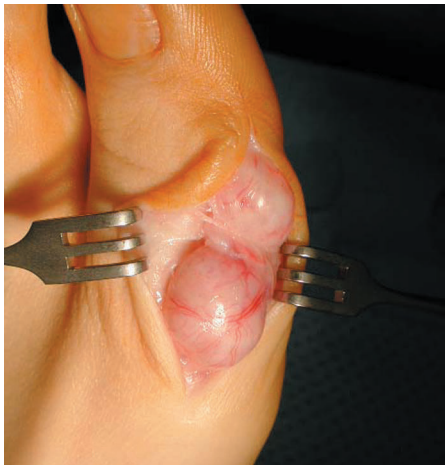

Figure 41.10 Angioleiomyoma of the hallux.

Tumours

The most common benign tumours of the foot are ganglia, giant cell tumour and angioleiomyomas (***Figure 41.10***); these tumours may need surgical excision.

Pigmented villonodular synovitis is a locally aggressive condition found in the ankle and is diagnosed by MRI or at histology. Imatinib medical therapy and en bloc resection are becoming more mainstream for cure rather than repeated arthroscopic suppression. Surveillance for recurrence is mandatory.

The most common 'tumour' seen in the foot is the plantar fibroma or Ledderhose's disease, which presents as a painful, often growing, lump in the sole along the plantar fascia. The condition is linked to Dupuytren's contracture and Peyronie's disease. Surgery should be avoided. Ultrasound or MRI will confirm the multifocal nature of the disease and exclude other pathology.

Any large or growing lump in the foot needs formal work-up along tumour guidelines, especially in the presence of night pain.

Infection

Septic arthritis in the foot or ankle is rare except in patients with diabetes and constitutes a surgical emergency; when it occurs it usually follows a surgical procedure but it can also arise as a result of haematogenous spread. Treatment is immediate surgical drainage and administration of appropriate high-dosage antibiotics once cultures are obtained.

Pierre Marie, 1853–1940, neurologist, Hospice de Bicêtre, Paris, France, later becoming Professor of Pathological Anatomy in the Faculty of Medicine, and finally, in 1918, Professor of Neurology.
Howard Henry Tooth, 1856–1925, physician, St Bartholomew's Hospital and the National Hospital for Nervous Diseases, London, UK, described peroneal muscular atrophy in 1886 independently of Charcot and Marie.
Sir Robert Jones, 1857–1933, British orthopaedic surgeon.
Russell A Hibbs, 1869–1932, Professor of Orthopedic Surgery, Columbia University, New York, NY, USA, described an operation for 'claw foot' in 1919.
Georg Ledderhose, 1855–1925, German surgeon, described this disease in 1894.
Baron Guillaume Dupuytren, 1777–1835, surgeon, Hôtel Dieu, Paris, France, described this condition in 1831.
François de la Peyronie, 1678–1747, surgeon to King Louis XIV of France and founder of the Royal Academy of Surgery, Paris, France.

The most common causative organism is *Staphylococcus aureus* with methicillin-resistant *S. aureus* (MRSA) becoming more common. Even with prompt treatment chondrolysis often occurs and subsequent degenerative changes develop rapidly.

In immunocompromised patients, opportunistic infections can arise and, in those with diabetes, failure to treat with debridement can lead to amputation. It is important to realise that radiographs in the early stages of infection are usually normal and that diagnosis is made on clinical suspicion and with blood tests and more sophisticated imaging such as MRI or bone scanning.

Tuberculosis can affect the foot and is associated with major bony damage; it responds surprisingly well to debridement and appropriate antituberculous therapy (***Figure 41.11***).

Figure 41.11 Tuberculosis of the foot (arrow).

Diabetes

Patients with diabetes have foot problems secondary to neuropathy and microvascular changes. They are at increased risk of infection and ulceration, and trauma (sometimes trivial) can lead to collapse of the foot, also known as Charcot neuroarthropathy (***Figure 41.12***).

Ulceration and amputation

Ulceration can lead to major morbidity and amputation (***Figure 41.13***). Ulcers need to be treated urgently, and when ulcer healing has occurred the aim should be to keep the foot ulcer free. NICE guidelines detail optimal management pathways with urgent admission and radiological and clinical assessment in a multidisciplinary team setting, followed by debridement, antibiotics if required and formal offloading. Ulceration is a surgical emergency and mandates immediate referral along NICE guidelines in the UK. Most amputations are preceded by ulceration.

Charcot

Charcot is a condition in which patients develop a neuropathic destruction of the joints. It is often described as painless but

Figure 41.12 Charcot foot: radiographs taken at the time of a trivial injury **(a)** and 6 weeks later **(b)**.

Figure 41.13 Diabetic foot ulcer.

actually the majority of patients have some pain. In the western world diabetes is the biggest cause but in the rest of the world leprosy is also important. However, any other neurological condition can cause this disease.

Charcot often presents with a hot, swollen, red extremity. It is often misdiagnosed as cellulitis, gout, fracture or DVT, and many present late because of the difficulty in diagnosis.

If there is no history of skin damage, infection is unlikely, but MRI and even biopsy can help differentiate between infection and Charcot. From initiation through to bone consolidation may take up to 18 months. The principle of treatment throughout is to maintain a foot-shaped foot to prevent late pressure ulcers. The acute Charcot foot requires appropriate splintage in a Charcot retaining orthotic walker (CROW) or a total contact cast (TCC), but many surgeons offer an aggressive early surgical approach if bony prominence/ulceration is thought to be inevitable. Surgical excision of a bony prominence dramatically reduces ulceration and amputation risk and reconstruction in the early phases of Charcot is now becoming more mainstream, but surgical risks are high. Long-segment fixation with implants and intramedullary nailing is now regularly undertaken. Failure of non-operative or operative treatment results in ulceration and amputation.

Summary box 41.9

Diabetes

- Patients with diabetes are prone to infection because of:
  - Peripheral neuropathy
  - Peripheral vascular disease
  - Impaired resistance to infection
- A Charcot foot is often misdiagnosed but is a surgical emergency and requires urgent admission and management
- An ulcer in a diabetic foot is a surgical emergency and requires urgent admission and management

Entrapment neuropathies

Any nerve supplying the foot can become entrapped and result in pain, and treatment often requires surgical decompression. Tarsal tunnel syndrome is much rarer than carpal tunnel syndrome and is confirmed with nerve conduction. A high proportion of patients retain neurology and pain despite release.

Heel pain

The commonest cause of heel pain is plantar fasciitis. Pain is located inferomedially within the heel and is worst first thing in the morning and after periods of rest. The majority of cases settle within 18 months and surgery is rarely required or successful. Ultrasound-guided injection or shockwave forms the mainstay of treatment for the non-resolving cases. The differential diagnosis list includes calcaneal stress fracture, tarsal tunnel syndrome, seronegative arthropathy and Ledderhose's disease.

FURTHER READING

Bulstrode C, Wilson MacDonald J *et al. Oxford textbook of trauma and orthopaedics*, 2nd edn. Oxford: Oxford University Press, 2017.

Miller MD, Thompson SR. *Miller's review of orthopaedics*, 8th edn. Philadelphia, PA: Elsevier, 2019.

Warwick D, Blom A, Whitehouse M. *Apley and Solomon's concise system of orthopaedics and trauma*, 5th edn. Abingdon: CRC Press, 2022.